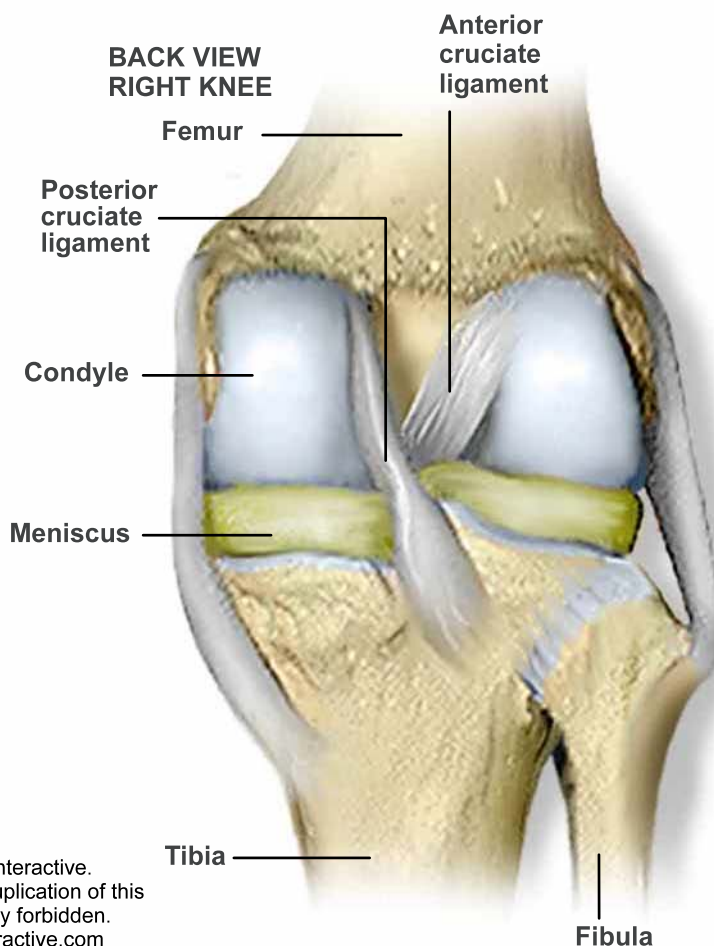
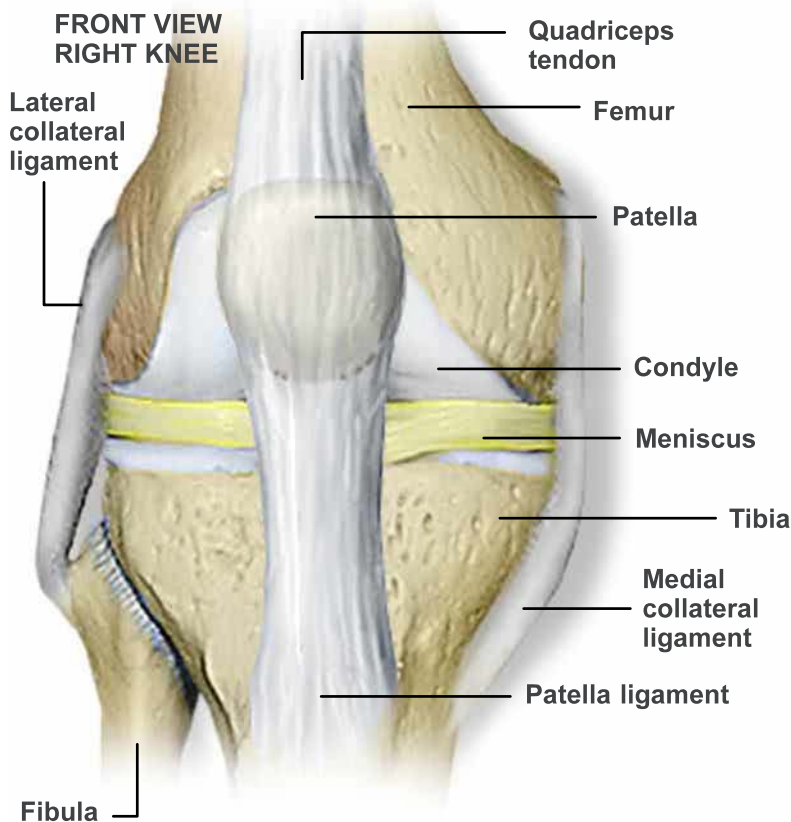


ANATOMY OF THE KNEE



BONES

Tibia

The tibia is the lower leg bone. Also called the shin bone, it is the second longest bone of the body, and is located below the knee.

Femur

The femur, also known as the thigh bone, is the longest, largest and heaviest bone of the body. It is located above the knee.

Fibula

The fibula is the thin bone located on the outside of the tibia.

Patella

The patella, or knee cap, is a bone that is connected to the patella ligament, below, and the quadriceps tendon, above. The underside of the patella has a smooth surface and glides over the knee joint when the leg is extended or bent.

SOFT TISSUE

Meniscus

The medial meniscus and the lateral meniscus act like cushions and distribute the weight of the femur.

Collateral ligaments

The lateral and medial collateral ligaments minimize side to side movement and help stabilize the knee.

Condyle

The condyle makes up the rounded end of the femur. This smooth surface allows the femur to move easily over the tibia's meniscus.

Patella ligament

The patella ligament helps secure the patella over the front of the knee joint.

Quadriceps tendon

This tendon connects the patella to the quadriceps femoral muscle above it. The muscle and tendon pull the patella over the front of the knee joint to extend the lower leg.

Posterior cruciate ligament

The posterior cruciate ligament (PCL) keeps the tibia from sliding backward.

Anterior cruciate ligament

The anterior cruciate ligament (ACL) connects the front of the tibia to the back of the femur. It keeps the tibia from sliding forward and limits its rotation.